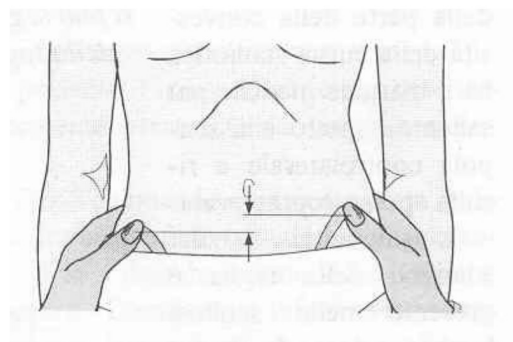
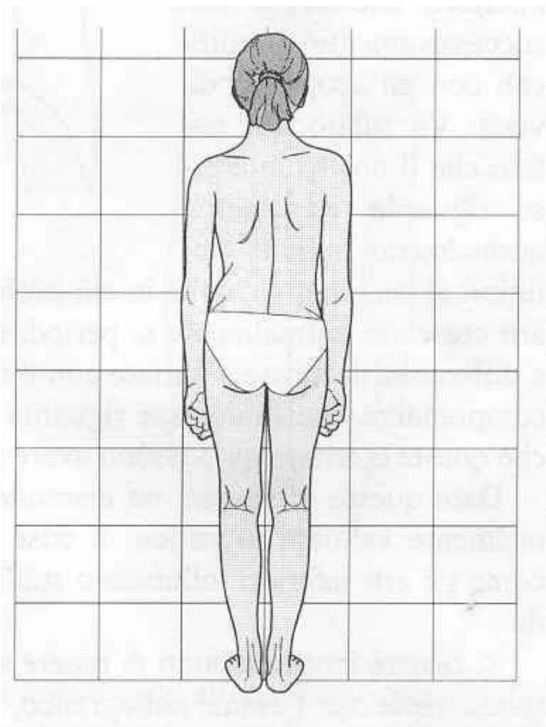
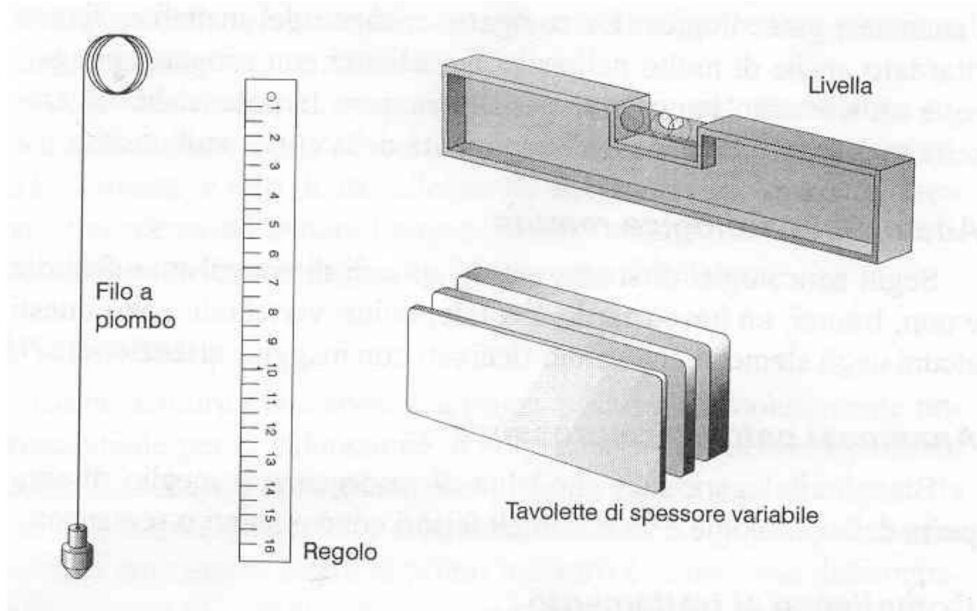
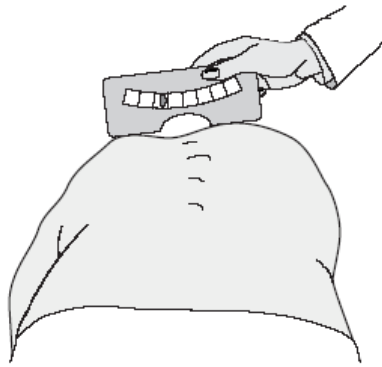
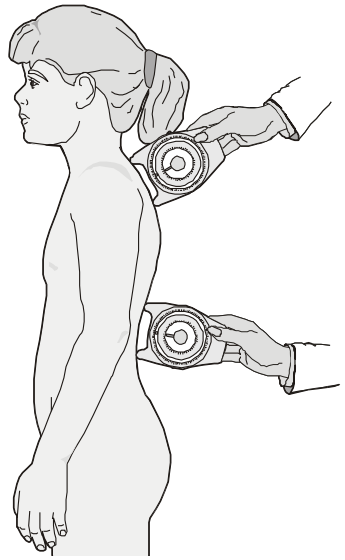
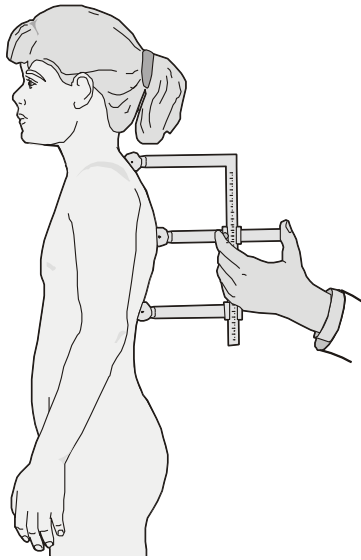
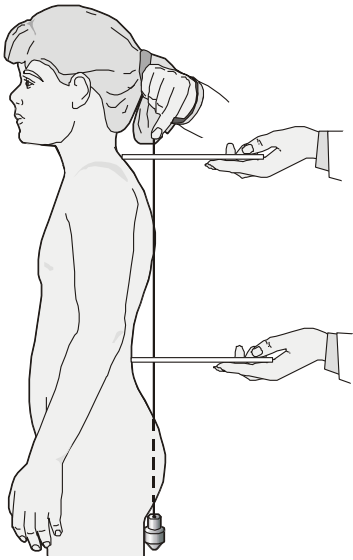


La scoliosi idiopatica adolescenziale: strumenti di valutazione, protocolli operativi ed esercizi specifici

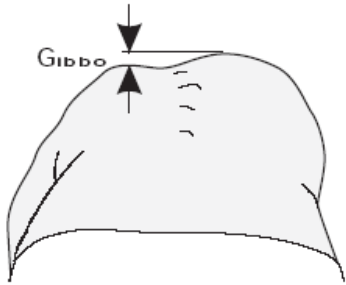
Milano, 9 novembre 2013

Valutazione clinica

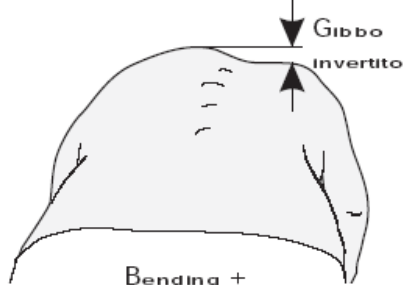




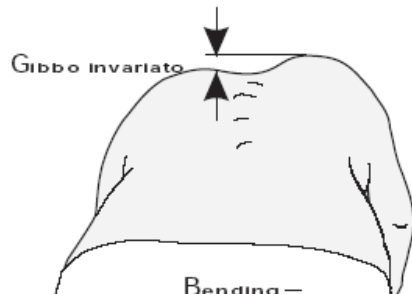
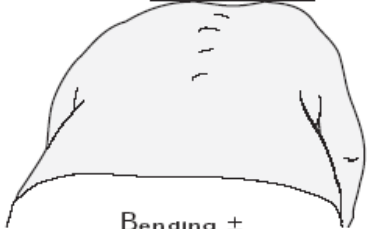
In bending anteriore



In bending laterale



Scomparsa del gibbo



Bending -

TRACE (Trunk Aesthetic Clinical Evaluation)

Figura 1

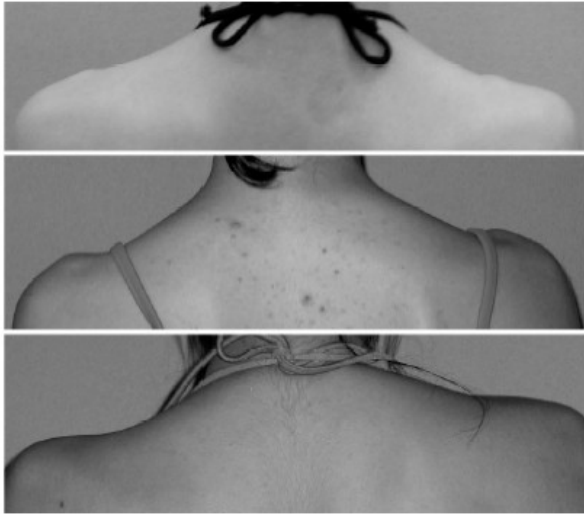


Figura 2

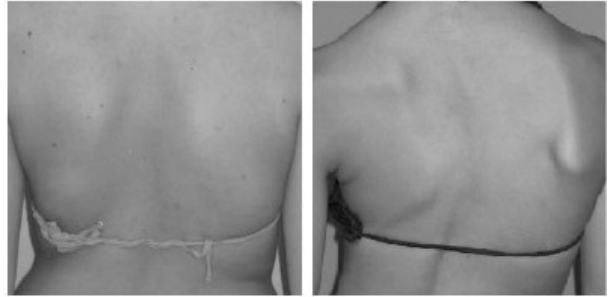


Figura 3

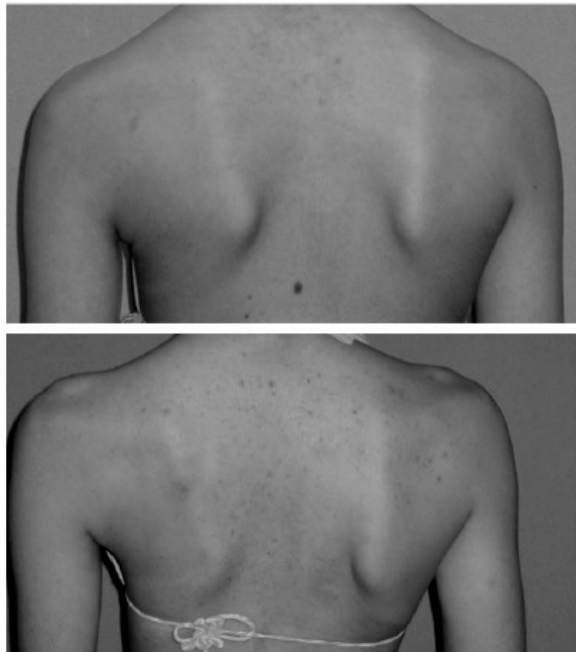


Figura 4

