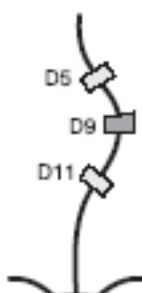
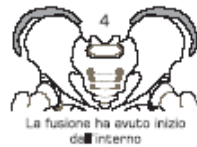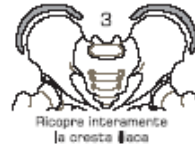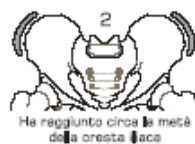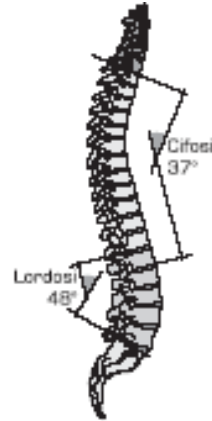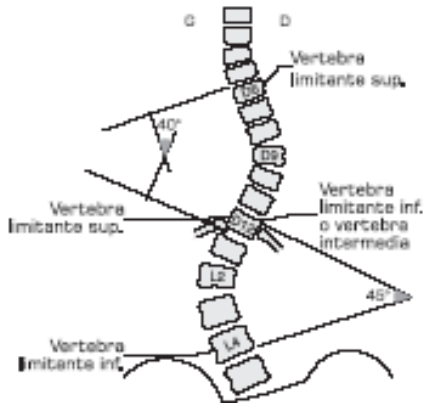


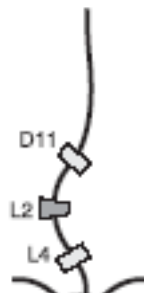
La scoliosi idiopatica adolescenziale: strumenti di valutazione, protocolli operativi ed esercizi specifici

Milano, 9 novembre 2013

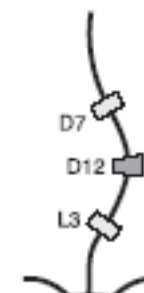Valutazione radiografica



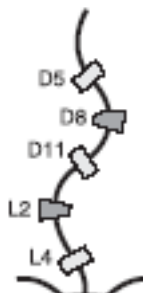
Dorsale Apicale da D2 a D11



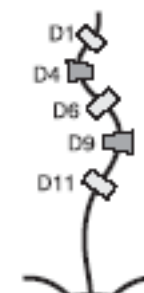
Lombare Apicale da L2 a L4



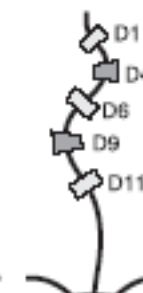Dorso-Lombare Apicale da D12 a L1



Dorsale e Lombare



Doppia dorsale di Moir



Doppia dorsale di Moir inversa

